



Anti-hepatofibrotic effect of ethyl acetate fraction of *Bombax costatum* Pellgr.EtVuillet stem bark against CCl₄-induced liver fibrosis in mice

Nuhu Mohammed^{*1}, Joseph Akpojo Anuka¹, Aliyu Muhammad Musa², Jamilu Yau¹

¹Department of Pharmacology and Therapeutics, Ahmadu Bello University Zaria, Nigeria;

*Email: nuhumhd8@gmail.com

²Department of Pharmaceutical and Medicinal Chemistry, Ahmadu Bello University Zaria, Nigeria;

ARTICLE INFO

Type: Original Research

Topic: Medicinal Plants

Received June 11th 2020

Accepted September 29th 2020

Key words:

- ✓ *Bombax costatum*
- ✓ Carbon tetrachloride
- ✓ Ethyl acetate
- ✓ Fibrosis
- ✓ Mice

ABSTRACT

Background & Aim: *Bombax costatum* stem bark is traditionally used in treatment of liver diseases but the anti-hepatofibrotic effect of its ethyl acetate fraction has not been scientifically evaluated. This study aimed to evaluate the anti-hepatofibrotic effect of ethyl acetate fraction of *B. costatum* stem bark (EAB) against carbon tetrachloride (CCl₄) induced liver fibrosis in mice.

Experimental: Normal control group were administered olive oil while mice in the remaining groups received 0.4 ml/kg of CCl₄ twice weekly for 6 weeks. Mice in treatment groups received EAB once daily orally for the next 2 weeks at doses of 31.25, 62.5 and 125 mg/kg body weight, respectively. Mice in standard control group received silymarin (100 mg/kg) daily for the next 2 weeks. Mice in toxic control group were sacrificed 72 hours after the last dose of CCl₄ while mice in CCl₄ control group were observed for the next 2 weeks for spontaneous resolution of fibrosis. Effect of treatment on tumor necrosis factor- α (TNF α), transforming growth factor- β 1 (TGF β 1), malondialdehyde (MDA), reduced glutathione (GSH) levels and liver histopathology were evaluated.

Results: CCl₄ intoxication caused significant (P<0.05) elevation in TNF α , TGF β 1 and MDA with associated collagen deposition in the liver. Administration of EAB significantly (P<0.05) decreased the level of TNF α , TGF β 1 as well as MDA and increased GSH level compared to CCl₄ toxic group.

Recommended applications/industries: Ethyl acetate fraction of *B. costatum* possesses anti-hepatofibrotic, anti-inflammatory and in vivo anti-oxidant activities against CCl₄ induced liver fibrosis.

1. Introduction

Liver fibrosis is a complication of chronic liver injury characterised by excessive deposition of collagen in the liver. Repeated and progressive liver injury can activate the inflammatory cells and cause release of profibrogenic cytokines such as transforming growth factor - β 1 (TGF β 1) thereby leading to liver fibrosis irrespective of the initiating stimulus. TGF β 1 is a potent mediator of fibrosis in the liver (Brenner, 2009)

and it is involved in the activation of quiescent hepatic stellate cells (HSC) to myofibroblast (Bataller and Brenner, 2005). Despite the fact that liver fibrosis can progress to cirrhosis and ultimately to hepatocellular carcinoma (Samuele *et al.*, 2012), effective and affordable anti-hepatofibrotic therapy have not been developed yet. Liver transplantation (which is expensive and not easily accessible in most developing countries) is the life-saving treatment for end-stage liver diseases (Kling *et al.*, 2017). As a result of these,

the search for new effective, accessible and affordable therapy with minimal side effect is still in progress. Inhibition of HSC activation and modulation of TGF β 1 signalling pathway could be a promising therapeutic target in liver fibrosis.

Bombax costatum (BC) is a widely used medicinal plant belonging to the family Bombacaceae. The stem bark of the plant is used in African traditional medicine in treating liver diseases (Dalziel, 1985). Methanol stem bark extract of *B. costatum* was reported to possess hepatoprotective activity against carbon tetrachloride (CCl₄) induced acute liver injury in rats. Lower doses of the extract were also noted to exhibit more hepatoprotective activity (Mohammed *et al.*, 2018). We therefore screened the fractions of *B. costatum* for hepatoprotective activity against CCl₄ induced acute liver injury in mice and found its ethylacetate (EA) fraction to have the highest hepatoprotective activity at relatively low concentration.

This study therefore aimed to evaluate the anti-hepatofibrotic activity of EA fraction of *B. costatum* against CCl₄ induced liver fibrosis in mice.

2. Materials and Methods

2.1. Experimental Animals

Swiss albino male mice (25-30 g) were obtained from Animal Facility of Department of Pharmacology and Therapeutics, Ahmadu Bello University Zaria. The animals were kept in clean cages with metal coverlids and bedded with soft wood shavings. They were kept in a well-ventilated room and fed with standard commercial mice feed (Vital feed[®], Zaria). The mice were allowed free access to drinking water *ad libitum*. All experiment protocols were approved by the Ahmadu Bello University Committee for Animal Use and Care (Approval number: ABUCAUC/2020/50).

2.2. Preparation of methanol stem bark extract of *B. costatum*

Bombax costatum stem bark was collected from Hanwa area of Sabon-Gari local Government, Kaduna, Nigeria. It was authenticated by a taxonomist at the Herbarium Unit of the Department of Botany, Ahmadu Bello University, Zaria. A voucher specimen number (1211) was assigned to the plant after comparing it with a specimen deposited in the Herbarium Unit for future

reference. The stem bark of the plant was air dried under shade, mechanically powdered (using mortar and pestle) and stored in an air tight container. Methanol extract of *B. costatum* stem bark was prepared by subjecting 11 kg of the powdered stem bark to maceration using 40 L of 70% methanol (Sigma Aldrich, USA) for 72 hours. The mixture was intermittently stirred during the 72 hours period and then filtered using Whatman filter paper (Grade 1). The filtrate was concentrated to dryness over a water bath maintained at 45°C. The extract was kept in an air tight container and then stored in a desiccator until required for further studies.

2.3. Fractionation of methanol stem bark extract of *B. costatum*

To obtain the EA fraction of BC, 460g of methanol stem bark extract of *B. costatum* was subjected to liquid-liquid partitioning sessions using separating funnel (1000 ml). For each session, 92 g of the extract was dissolved in 500 ml of distilled water and exhaustively partitioned (3 times) sequentially with 500 ml each of hexane, chloroform, ethyl acetate and *n*-butanol. For each solvent, the mixture was allowed to stand for 30 min in the separating funnel until a fine separation line appeared. The solvent fractions were evaporated to dryness on a water bath maintained at 45°C to obtain their corresponding fractions (Gandhi *et al.*, 2003)

2.4. Anti-hepatofibrotic studies

The anti-hepatofibrotic study was conducted as previously described (Domitroviic *et al.*, 2009) with some modifications. Thirty five male mice were randomly divided into 7 groups containing 5 mice each. Mice in group I received 0.4 ml/kg of olive oil intraperitoneally (*i.p*) twice weekly for 6 weeks (Normal control). Mice in group II received 0.4 ml/kg of CCl₄ (BDH Ltd Poole, England) in olive oil (1:1, v/v) *i.p* twice weekly for 6 weeks and were euthanized 72 hours after the last dose of CCl₄ (Toxic control). Mice in group III received 0.4 ml/kg of CCl₄ in olive oil (1:1, v/v) *i.p* twice weekly for 6 weeks and were observed for spontaneous resolution of fibrosis for the next 2 weeks (CCl₄ control). Mice in group IV received 0.4 ml/kg of CCl₄ in olive oil (1:1, v/v) *i.p* twice weekly for 6 weeks and also received silymarin (Micro Labs Limited, India) orally (100mg/kg) daily for the next 2 weeks (Standard control). Mice in group V-VII

received 0.4 ml/kg of CCl₄ in olive oil (1:1, v/v) *i.p* twice weekly for 6 weeks and then received EA fraction of *B. costatum* orally at 31.25, 62.5 and 125 mg/kg respectively daily for the next 2 weeks. At the end of the 8 weeks period, the remaining mice were euthanized under chloroform anaesthesia 24 hours after the last treatment. The liver and blood samples were collected for analysis. The blood samples were collected and allowed to clot at room temperature for 2 hours and centrifuged at 1000 g for 20 min to obtain serum for determination of TNF- α , hepatic malondialdehyde (MDA) levels and hepatic reduced glutathione (GSH). The liver tissues were then dissected and the left lobe was fixed in a buffer solution of 10% formalin for histological analysis with Masson's trichrome stain. For each liver, about 0.7 g of the liver tissue was homogenized in a phosphate buffer solution (PBS) (0.01 M, pH 7.4) with a glass homogenizer. The homogenates was centrifuged at 5000 g for 5 min. The supernatant was stored at -20°C for determination of liver TGF β 1 content using ELISA kit (Wuhan Fine Biological Technology Co., Ltd. China) according to manufacturer's instruction.

2.5. Histopathological analysis

Sections of liver tissues were fixed in 10% buffered formalin (pH 7.2) and dehydrated through a series of ethanol solutions (70%, 90%, 96% and absolute). The tissues were cleared in xylene and embedded in paraffin. Sections of 5 μ m thickness were cut and stained with Masson's trichrome stain for examination. The stained tissues were observed through a Leitz microscope (x250).

2.6. In vivo anti-oxidant studies

2.6.1. Determination of reduced glutathione (GSH)

Determination of GSH in serum was done according to the colorimetric method of Ellman (1959). 150 μ l of serum from each mouse was added to 1.5 ml of 10% trichloroacetic acid and centrifuge at 1500 g for 5 min. 1ml of the supernatant was treated with 0.5 ml of Ellman's reagent and 3ml of phosphate buffer (0.2 M, pH 8.0). Absorbance of solutions was measured at 412 nm against blank. Absorbance values were compared with a standard curve generated from known GSH.

2.6.2. Determination of hepatic malondialdehyde (MDA)

The lipid peroxides content in the mice serum were determined by monitoring thiobarbituric acid reactive substance formation as described by Okhawa (1979) with slight modification by Atawodi *et al.*, (2011). 2 ml of 15% trichloroacetic acid was measured in to a test tube, 2 ml of thiobabitutric acid (TBA) was added and 100 μ l of mouse serum was added. The mixture was incubated at 80°C for 30 min in a water bath and allowed to cool, followed by centrifugation at 3000 rpm for 10 min. The upper organic layer was taken and its absorbance was taken at 535 nm against an appropriate blank without the sample. The levels of lipid peroxides was expressed as n moles of thiobarbituric acid reactive substances (TBARS)/mg protein using an extinction coefficient of 1.56 $\times 10^5$ ML cm⁻¹.

2.6.3. Determination of catalase

This was measured using Abebi's method (1974). 10 μ l of serum was added to a test tube containing 2.8 ml of 50 mM potassium phosphate buffer (pH 7.0). The reaction was initiated by adding 0.1 ml of freshly prepared 30 Mm hydrogen peroxide (H₂O₂) and the decomposition rate of H₂O₂ was measured at 240 nm for 5min on a spectrophotometer. A molar extinction coefficient ϵ of 0.041 nM⁻¹ was used to calculate the catalase activity.

2.7. Analysis of data

Data were presented using tables and figures where applicable. Analyses of data were done using one way ANOVA followed by Tukey's post hoc test (where significant difference exists). The results were considered significant at *p*-values ≤ 0.05 . The results were presented as mean \pm standard error of the mean (S.E.M.).

3. Results and discussion

The stem bark of *B. costatum* is used in African traditional medicine in the treatment of liver diseases. This study was designed to evaluate the anti-hepatofibrotic activity of ethyl acetate fraction of *B. costatum* stem bark using CCl₄ induced liver fibrosis model. The percentage yield of ethyl acetate fraction of *B. costatum* stem bark was found to be 5.09%.

CCl₄ is a toxicant that is bioactivated by cytochrome P450 2E1 to form trichloromethyl free radicals and

reactive oxygen species (ROS), which can cause damage to hepatocellular membranes, activation of immune cells and release of proinflammatory mediators. CCl₄ induced liver fibrosis model is a widely used *in vivo* model of liver fibrosis in rodents. Intraperitoneal administration of carbon tetrachloride 2 to 3 times per week during 4 to 6 weeks duration at a dose range of 300-1000 µl/kg can lead to liver fibrosis in mice (Constandinou *et al.*, 2005).

In this study, intraperitoneal administration of CCl₄ to mice at a dose of 0.4 ml/kg twice weekly for 6 weeks caused significant ($P < 0.05$) increase in level of TGF-β1 (1488±239.0) compared to normal control group that received olive oil (288±58.3). Administration of EA fraction of *B. costatum* at dose of 125 mg/kg for 2 weeks after induction of liver fibrosis caused significant ($P < 0.05$) reduction in the level of TGF-β1 (347±83.8) compared to CCl₄ toxic group (1488±239.0). No significant reduction in level of TGF-β1 was observed after 2 weeks observation of CCl₄ control group, treatment with silymarin at 100 mg/kg as well as treatment with EA fraction of *B. costatum* at 31.25 mg/kg and 62.5 mg/kg when compared with CCl₄ toxic group (Fig. 1).

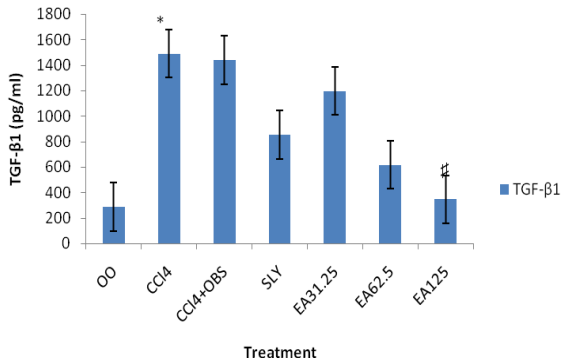


Figure 1. Effect of EA fraction of *B. costatum* on TGF-β1 in CCl₄ induced hepatofibrosis in mice.

Data were presented as Mean ± SEM. (n = 5), One way ANOVA followed by Tukey's post hoc test, * = $P \leq 0.05$ compared to normal control group, # = $P \leq 0.05$ compared to CCl₄ toxic group. TGF-β1: Transforming growth factor beta 1, OO: Olive oil, SLY: Silymarin, BC: Methanol stem bark extract of *Bombax costatum*, EA: Ethyl acetate fraction of *Bombax costatum*, OBS: Observation, CCl₄: Carbon tetrachloride

Photomicrograph of liver tissue from the normal control group showed normal liver (Fig. 2a). The significant reduction in TGF-β1 level with corresponding resolution of established fibrosis (Fig. 2g) in the EA fraction of *B. costatum* treated group (at

125 mg/kg) could be due to down regulation of the TGFβ1 signalling pathway of liver fibrosis. TGF β1 is reported to be a potent mediator of fibrosis in the liver (Brenner, 2009).

Intraperitoneal injection of CCl₄ at a dose of 0.4 ml/kg twice weekly for 6 weeks also caused significant ($P < 0.05$) increase in level of TNFα (88.0±3.74) compared to normal control group. Oral administration of silymarin at dose of 100 mg/kg for 2 weeks after induction of liver fibrosis caused significant ($P < 0.05$) reduction in the level of TNFα (52.8±6.26) when compared with CCl₄ toxic group (88.0±3.74). However, significant ($P < 0.05$) decrease in level of TNFα was observed in CCl₄ control group (49.8±6.76) when compared with CCl₄ toxic group. There was also significant ($P < 0.05$) reduction in level of TNFα after 2 weeks treatment with EA fraction of *B. costatum* at 62.5 and 125 mg/kg (50.4±6.49 and 49.2±4.92), respectively, when compared with CCl₄ toxic group (88.0±3.74) (Table 1).

Table 1. Effect of EA fraction of *B. costatum* on TNFα in CCl₄ induced liver fibrosis in mice

Treatment	TNFα (pg/ml)
OO	37.0±6.24
CCl ₄	88.0±3.74a
CCl ₄ + OBS	49.8±6.76b
SLY	52.8±6.26b
EA31.25mg/kg	56.0±8.12
EA62.5mg/kg	50.4±6.49b
EA125mg/kg	49.2±4.92b

Data were presented as Mean ± SEM. (n = 5), One way ANOVA followed by Tukey's post hoc test, a = $P \leq 0.05$ compared to normal control group, b = $p \leq 0.05$ compared to CCl₄ toxic group.

TNFα = Tumour necrosis factor alpha; OO= Olive oil; SLY= Silymarin; EA= Ethyl acetate fraction of *Bombax costatum*; OBS= Observation; CCl₄ = Carbon tetrachloride.

The observed increase in levels of TNF-α and TGF-β1 with associated collagen deposition in the liver could be due to activation of kupffer cells and HSC from repeated administration of CCl₄. These observations were consistent with findings of previous studies (Demirenen *et al.*, 2014; Nanik *et al.*, 2018) where TNF-α and TGF-β1 were also observed to be significantly elevated following repeated intraperitoneal administration of CCl₄. The level of TNF-α level in CCl₄ control group was observed to be reduced spontaneously although the progression of liver fibrosis was observed on histopathological study. This could be due to role of TNF-α in multiple

signalling pathways of inflammation, proliferation and apoptosis of liver cells (Yang and Seki, 2015).

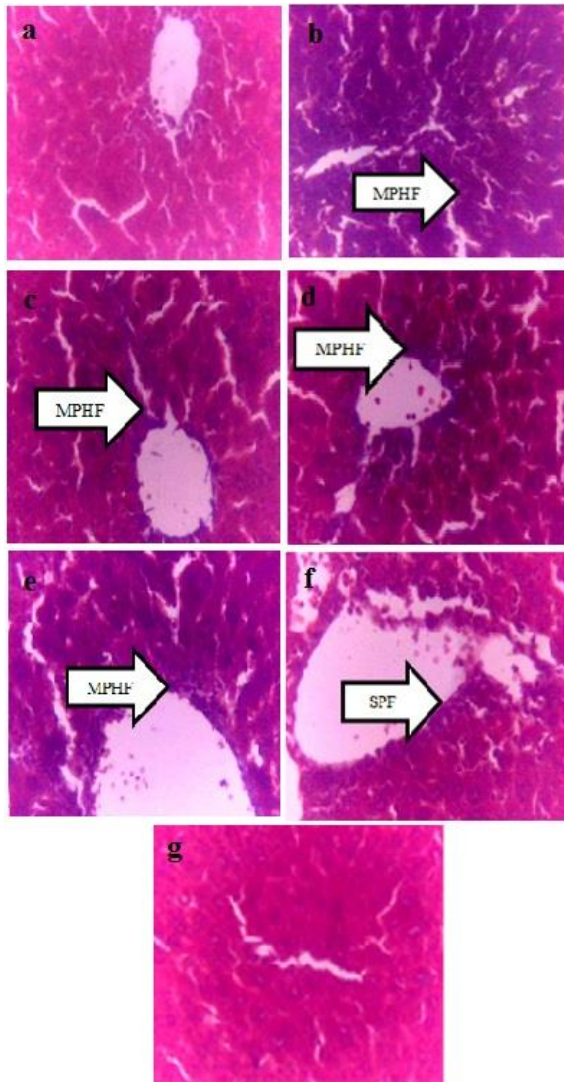


Figure 2. Photomicrograph of liver showing effect of ethylacetate (EA) fraction of *B. costatum* in CCl₄-Induced liver fibrosis in mice (Masson's Trichrome ×250). (2a) OO: Normal liver, (2b) CCl₄: Moderate porto-hepatic fibrosis (MPHF), (2c) CCl₄ + Observation: Moderate porto-hepatic fibrosis (MPHF), (2d) SLY 100 mg/kg: Moderate porto-hepatic fibrosis (MPHF), (2e) EA 31.25 mg/kg: Moderate portal fibrosis (MPF), (2f) EA 62.5 mg/kg: Slight portal fibrosis (SPF), (2g) EA 125 mg/kg: Normal Liver. OO= Olive oil; SLY= Silymarin; EA=Ethyl acetate; CCl₄= Carbon tetrachloride

In agreement with results of the biochemical findings, twice weekly administration of 0.4 ml/kg of CCl₄ for 6 weeks to mice also caused moderate deposition of collagen at the portal area extending into

the liver parenchyma (Fig. 2b) when compared with liver tissue from normal control group (Fig. 2a). Subsequent observation of the mice for 2 weeks period after induction of fibrosis (for spontaneous resolution of fibrosis) showed persistence of moderate Porto-hepatic fibrosis (Fig. 2c). Additionally, treatment with silymarin (100 mg/kg for 2 weeks) after fibrosis induction did not reverse liver fibrosis (Fig. 2d). Treatment with EA fraction of *B. costatum* at 31.25 mg/kg for 2 weeks (after induction of fibrosis) resulted to moderate portal fibrosis (Fig. 2e) while treatment with the EA fraction of at 62.5 mg/kg resulted to slight portal fibrosis (Fig 2f). However, treatment with EA fraction of *B. costatum* at 125 mg/kg for 2 weeks resulted in restoration of normal liver architecture (Fig 2g). The spontaneous reduction in TNF- α level seen in the CCl₄ control group has demonstrated that terminating further liver damage caused by toxicants could lead to some resolution of inflammation in the liver but not spontaneous resolution of advanced fibrosis. The observed progression of liver fibrosis in the CCl₄ control group is consistent with the finding of Domitrovic *et al.* (2009). Once advanced fibrosis is established, collagen deposition progresses leading to the formation of hepatic nodules and decreased blood supply to the liver (Bataller and Brenner, 2005; Hernandez-Gea and Friedman, 2011).

Reactive oxygen species are key driver of hepatic inflammation and fibrosis. Lipid peroxidation in the liver can be assessed by measuring the level of MDA. CCl₄ can damage hepatocellular membrane and cause lipid peroxidation leading to elevation in hepatic MDA. Administration of CCl₄ at a dose of 0.4 ml/kg twice weekly for 6 weeks caused significant ($P<0.05$) increase in level of MDA (1153.0 ± 320.0) compared to normal control group that received olive oil (235.5 ± 20.9). However, oral treatment with silymarin (100 mg/kg) and EA fraction of *B. costatum* at all tested doses for 2 weeks after induction of liver fibrosis caused significant ($P<0.05$) reduction in the level of MDA compared to CCl₄ toxic group (1153.0 ± 320.0). There was no significant ($P>0.05$) reduction in level of MDA after 2 weeks observation of CCl₄ control group (compared to CCl₄ toxic group) suggesting the persistence of oxidative stress (Table 2). The observed significant reduction in level of hepatic MDA in silymarin and EA fraction of *B. costatum* (125 mg/kg) treated groups could be due to presence of flavonoid in

them. *B. costatum* stem bark was reported to possess bioactive constituents such as flavonoids and tannins (Mohammed *et al.*, 2018) with antioxidant potentials due to their free radical scavenging activity (Kahkonen

et al., 1999). Hepatic MDA levels are reduced by agents that possess antioxidant properties as seen in results of previous studies (Morsy *et al.*, 2012; Chavez *et al.*, 2008).

Table 2. Effect of EA fraction of *B. costatum* on MDA, CAT and GSH in CCl₄ induced liver fibrosis in mice.

Treatment	MDA(nMol/ml)	CAT(U/ml)	GSH(U/ml)
OO	235.5±20.90	14.00±0.65	19.99±0.54
CCl ₄	1153.0±320.00 [*]	5.49±1.15 [*]	9.55±0.45 [*]
CCl ₄ + OBS	776.0±102.00	9.20±1.58	12.44±1.61
SLY	271.1±26.60 [#]	13.05±1.09	18.79±0.29 [#]
EA 31.25mg/kg	485.0±110.00 [#]	10.64±2.78	12.76±2.41
EA 62.5mg/kg	417.21±2.84 [#]	11.27±0.67	15.14±1.29
EA 125mg/kg	273.2±36.40 [#]	11.98±2.22	18.03±1.23 [#]

Data were presented as Mean ± SEM. (n = 5), One way ANOVA followed by Tukey's post hoc test. a = $p \leq 0.05$ when compared with normal control group, b = $p \leq 0.05$ compared to CCl₄ toxic group.

MDA= Malondialdehyde; GSH= Reduced glutathione; OO= Olive oil; SLY= Silymarin; EA= Ethyl acetate fraction of *B. costatum*; OBS= Observation; CCl₄ = Carbon tetrachloride.

A significant ($P < 0.05$) decrease in GSH (9.55±0.45) and CAT (5.49±1.15) was observed after intraperitoneal administration of CCl₄ at a dose of 0.4 ml/kg twice weekly for 6 weeks when compared with normal control group (19.99±0.54 and 14.00±0.65, respectively). However, administration of silymarin (100 mg/kg) and 125 mg/kg of EA fraction of *B. costatum* for 2 weeks after induction of liver fibrosis caused significant ($P < 0.05$) increase in the level of GSH (Table 2).

There was an appreciable increase in level of CAT (though not statistically significant) after 2 weeks treatment with silymarin (100 mg/kg) and EA fraction of *B. costatum* stem bark at all tested doses when compared to CCl₄ toxic group (Table 2). The significant increase in the level of GSH in the EA fraction treated groups could be as a result of their antioxidant activities.

4. Conclusion

In conclusion, ethylacetate fraction of *B. costatum* possess anti-hepatofibrotic, anti-inflammatory and *in vivo* antioxidant activities in a dose dependent manner. This provides scientific basis for the traditional use of the plant in treatment of liver diseases.

5. Acknowledgement

The authors acknowledge the technical assistance of Salihu Abdullahi and Nazifi Abdullahi of the

Department of Pharmacology and Therapeutics, as well as Kabiru Muhammad of Department of Pharmacognosy and Drug Development, Ahmadu Bello University, Zaria.

6. References

- Abebi, H.E. 1974. *Catalase. Methods of Enzymatic Analysis*. New York Academic Press, New York.
- Atawodi, S.E., Adekunle, O.O and Bala, I. 2011. Antioxidant, organ protective and ameliorative properties of methanol extract of *Anogeissus leiocarpus* stem bark against carbon tetrachloride-induced liver injury. *International Journal of Pharmaceutical Science Research*, 2(6):1443-1448.
- Bataller, R. and Brenner, D.A. 2005. Liver fibrosis. *Journal of Clinical Investigation*, 115:209–218.
- Brenner, D.A. 2009. Molecular pathogenesis of liver fibrosis. *Transactions of the American Clinical and Climatological Association*, 120:361-368.
- Chavez, E., Reyes-Gordillo, K. and Segovia, J. 2008. Resveratrol prevents fibrosis, NF- κ B activation and TGF- β increases induced by chronic CCl₄ treatment in rats. *Journal of Applied Toxicology*, 28(1): 35–43.
- Constandinou, C., Henderson, N. and Iredale, J.P. 2005. Modeling liver fibrosis in rodents. *Methods in Molecular Medicine*, 117:237–250.
- Dalziel, J.M. 1985. *The Useful Plants of West Tropical Africa*. Vol 1. Kew: Royal Botanic Gardens.
- Demirenen, K., Dogan, Y., Kocamaz, H., Ozercan, I.H., Ilhan, S., Ustundag, B. and Bahcecioglu, I.H. 2014.

- Protective effects of L-carnitine, N-acetylcysteine and genistein in an experimental model of liver fibrosis. *Clinics and Research in Hepatology and Gastroenterology*, 38 (1): 63–72.
- Domitrovic, R., Jacobac, H., Tomac, J. And Sain, I. 2009. Liver fibrosis in mice induced by carbon tetrachloride and its reversion by luteolin. *Toxicology and Applied Pharmacology*, 241: 311–321.
- Ellman, G.L. 1959. Tissue sulfhydryl groups. *Archives of Biochemistry and Biophysics*, 82(1): 70-77.
- Gandhi, A.P., Joshi, K.C., Jha, K., Parihar, V.S., Srivastav, D.C., Raghunadh, P. and Tripathi, R.N. 2003. Studies on alternative solvents for the extraction of oil-I soybean. *International Journal of Food Science and Technology*, 38(3):369-375.
- Hernandez-Gea, V. and Friedman, S.L. 2011. Pathogenesis of liver fibrosis. *Annual Review of Pathology*, 6:425–456.
- Kahkonen, M.P., Hopia, A.I., Vuorela, H.J., Rauha, J.P., Pihlaja, K., Kujala, T.S. and Heinonen, M. 1999. Antioxidant activity of plant extracts containing phenolic compounds. *Journal of Agricultural and Food Chemistry*, 47: 3954–3962.
- Kling, C.E., Perkins, J.D., Carither, R.L., Donovan, D.M. and Sibulesky, L. 2017. Recent trends in liver transplantation for alcoholic liver disease in the United States. *World Journal of Hepatology*, 9(36): 1315-1321.
- Mohammed, N., Yaro, A.H. and Nazifi, A.B. 2018. *Bombax costatum* Pellegr. and Vuillet stem bark extract prevents paracetamol and carbon tetrachloride-induced liver injury in rats. *Tropical Journal of Natural Product Research*, 2(5): 220-226.
- Morsy, M.A., Abdalla, A.M., Mahmoud, A.M., Abdelwahab, S.A. and Mahmoud, M.E. 2012. Protective effects of curcumin, α - lipoic acid, and N-acetylcysteine against carbon tetrachloride induced liver fibrosis in rats,” *Journal of Physiology and Biochemistry*, 68(1): 29–35.
- Nanik, S., Vivian, S., Melva, L., Bantari, W.W. and Raymond, R.T. 2018. Protective effect of *Phaleria macrocarpa* water extract (Proliverenol) against carbon tetrachloride-induced liver fibrosis in rats: Role of TNF- α and TGF- β 1. *Journal of Toxicology*, 1-7.
- Samuele, D.M., Marco, M., Stefania, S., Chiara, R., Laura, A., Luciano, T. and Gianluca, S. 2012. Cellular and molecular mechanisms of hepatic fibrogenesis leading to liver cancer. *Translational Gastrointestinal Cancer*, 1:88-94.
- Yang, Y.M. and Seki, E. 2015. TNF α in liver fibrosis. *Current Pathobiology Reports*, 3(4): 253–261.